

## Severe hyperplastic tissue stenosis of a novel biodegradable esophageal stent and subsequent successful management with high-pressure balloon dilation

A 36-year-old man with chronic dysphagia secondary to achalasia (dysphagia grade 3) was referred for biodegradable stent placement after failed endoscopic management (high-pressure pneumatic balloon dilation, Rigiflex® [Microvasive Endoscopy, Boston Scientific, Natick, Massachusetts], 30 mm, 20 psi). He had declined surgical management. Endoscopy was performed and a 10-cm biodegradable stent (BD ELLA®, Ella-CS, Hradec Králové, Czech Republic) was placed across the gastroesophageal junction (● Fig. 1).

The patient was able to tolerate a soft diet post procedure (dysphagia grade 1) with a sustained clinical response to week 8. He then developed severe dysphagia and was soon unable to tolerate a liquid diet (dysphagia score 4). He presented with regurgitation, moderate weight loss, and pre-renal failure. Endoscopic examination revealed near-complete “in stent-stenosis” due to severe hyperplastic tissue ingrowth and stent collapse (● Fig. 2).

Celestin dilation (54 Fr) was initially performed but only gave minimal temporary relief. Surgical resection was considered. High-pressure balloon dilation (Rigiflex® 35 mm, inflation pressure 60 psi) was performed over a guide wire through the stenotic segment under fluoroscopic guidance (● Fig. 3).

The gastroscope passed easily into the stomach after dilation and the patient's dysphagia resolved immediately. Excellent symptom response has been sustained for over 8 months (no dysphagia). Patient outcomes after placement of self-expanding metal stents (SEMS) and self-expanding plastic stents (SEPS) for benign esophageal strictures are disappointing due to notable stent-related complications, including hyperplastic tissue ingrowth (SEMS) [1] and stent migration (SEPS) [2]. Novel self-expanding biodegradable stents are an alternative and may benefit patients with benign esophageal strictures and achalasia, and have the potential to become primary therapy, replacing other stent types and balloon dilation [3,4].

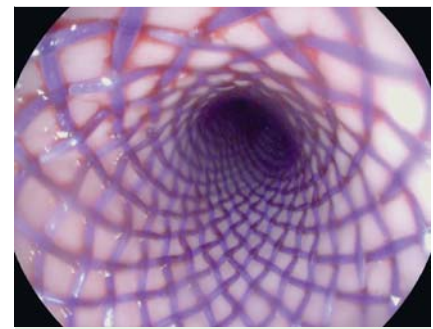
Biodegradable stents are thought to degrade within 8–10 weeks, thus preventing long-term tissue reaction and stenosis. However, hyperplastic tissue reaction occurs in conjunction with biodegradable stent degradation and the severity of the tissue response and the time to complete stent degradation, both important factors when considering patients for placement of a biodegradable stent, are not documented.

Hyperplastic tissue ingrowth occurs in up to 50% of SEMS placed for benign esophageal strictures [1]. While this tissue reaction is expected for biodegradable stents [5,6], ours is the first report of significant post-stent dysphagia due to stenosis. The early stent biodegradation should eliminate hyperplastic in-stent stenosis and the need for subsequent therapy. It is not clear what proportion of patients will suffer severe hyperplastic tissue reactions to cause early biodegradable stent stenosis. Nor is it clear whether there is a subset of patients with esophageal stenoses who may be at higher risk of such avid hyperplastic tissue response (e.g. achalasia). There have been anecdotal reports from Europe of similar reactions in achalasia, however no documentation in the literature. Management guidelines for severe biodegradable stent-related complications are required if we are to place these devices.

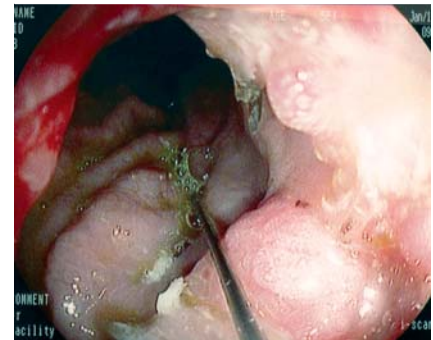
A severe biodegradable stent stenosis that causes near-complete dysphagia mandates immediate action such as dilation, local steroid injection or further stenting. There are no recommendations to guide what endoscopic approach is best. We propose that high-pressure achalasia balloon dilation can be used to dilate biodegradable stent-stenosis. Dysphagia may be completely resolved and sustained by using this approach.

**Competing interests:** None

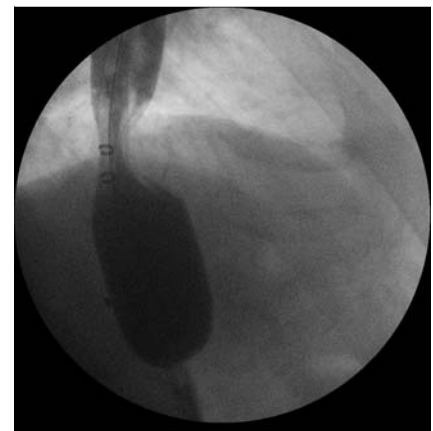
Endoscopy\_UCTN\_Code\_CCL\_1AB\_2AC\_3AB  
Endoscopy\_UCTN\_Code\_CPL\_1AH\_2AD



**Fig. 1** Fully expanded biodegradable stent (BD ELLA®) in distal esophagus.



**Fig. 2** ‘In-stent’ stenosis due to hyperplastic tissue reaction and stent collapse (distal stent in view).



**Fig. 3** High-pressure balloon esophageal dilation of ‘in-stent’ stenosis (Rigiflex®).

**C. S. Hair, D. A. Devonshire**

Department of Gastroenterology and Hepatology, Monash Medical Centre, Clayton, Victoria, Australia

## References

- 1 Song HY, Jung HY, Park SI *et al.* Covered retrievable expandable nitinol stents in patients with benign esophageal strictures: initial experience. *Radiology* 2000; 217: 551 – 557
- 2 Holm AN, de la Mora Levy JG, Gostout CJ *et al.* Self-expanding plastic stents in treatment of benign esophageal conditions. *Gastrointest Endosc* 2008; 67: 20 – 25
- 3 Cheng YS, Li MH, Chen WX *et al.* Temporary partially-covered metal stent insertion in benign esophageal stricture. *World J Gastroenterol* 2003; 9: 2359 – 2361
- 4 Murkherjee S, Kaplan DS, Parasher G, Sipple MS. Expandable metal stents in achalasia – is there a role? *Am J Gastroenterol* 2000; 95: 2185 – 2188
- 5 Fry SW, Fleischer DE. Management of a refractory esophageal stricture with a new biodegradable stent. *Gastrointest Endosc* 1997; 45: 179 – 182
- 6 Saito Y, Tanaka T, Andoh A *et al.* Usefulness of biodegradable stents constructed of poly-l-lactic acid monofilaments in patients with benign esophageal stenosis. *World J Gastroenterol* 2007; 13: 3977 – 3980

## Bibliography

DOI 10.1055/s-0029-1244011

Endoscopy 2010; 42: E132 – E133

© Georg Thieme Verlag KG Stuttgart · New York ·  
ISSN 0013-726X

## Corresponding author

**C. S. Hair, MD**

Department of Gastroenterology and Hepatology  
Monash Medical Centre

Clayton 3168

Victoria

Australia

Fax: +61-3-95946919

chris.hair@southernhealth.org.au