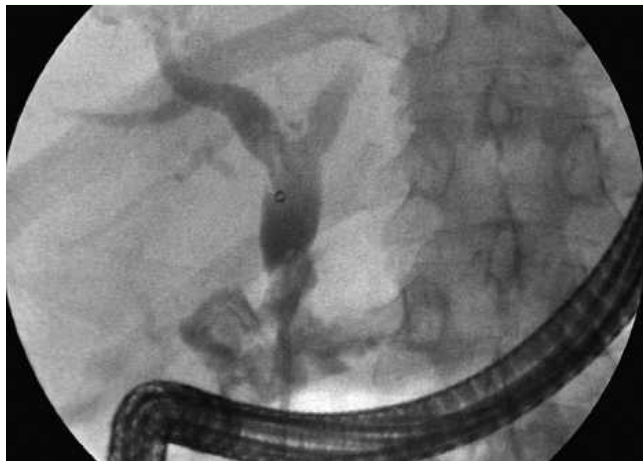
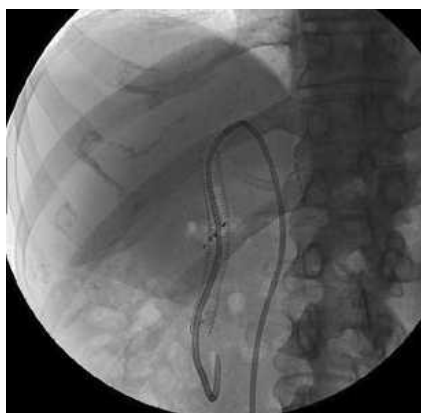
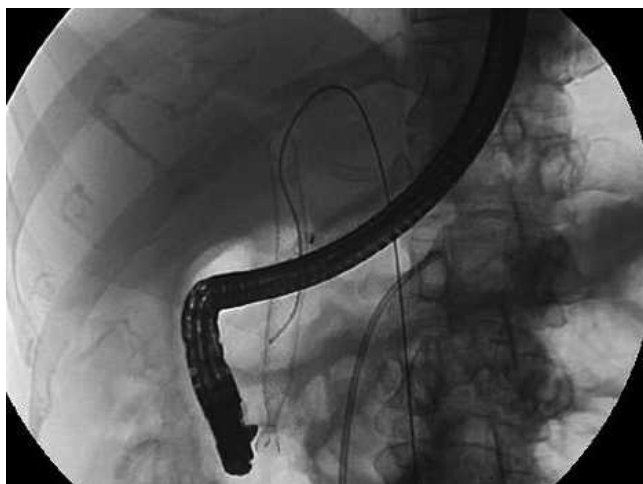
## Use of a self-expandable metallic stent for large bile leakage following orthotopic liver transplant



**Fig. 1** A large bile leak is visualized at endoscopic retrograde cholangiopancreatography (ERCP).



**Fig. 2** A self expandable metallic stent is placed.



**Fig. 3** The metallic stent is removed with a snare.

Biliary leaks are the most frequent complication after both liver transplantation and major liver surgery [1–3]. In the current literature, there are very few reports on the use of a metallic stent for large bile leakage, especially after liver transplantation [4,5].

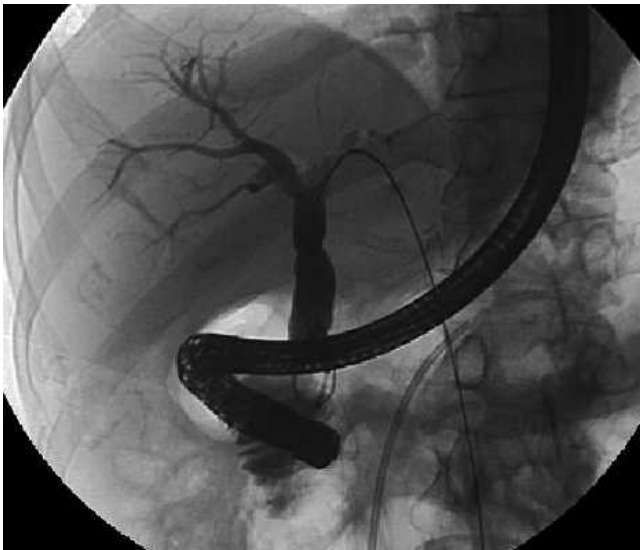We report a case of substantial biliary leakage following orthotopic liver transplantation, that was treated with a self-expanding metallic stent. Further studies are necessary to confirm the use of such metallic stents as a valid and safe treatment for bile leakage following liver transplant.

In 2007, a 61-year-old man underwent orthotopic liver transplantation with a choledocho-choledocho anastomosis for cirrhosis related to hepatitis B and hepatitis D virus (HBV and HDV).

The patient was admitted to our facility 1 month later because of fever and computed tomography (CT) evidence of a large perihepatic collection (7.8 × 3.5 mm). At admission, laboratory data were: aspartate aminotransferase (AST) 288 U/L (normal range 15–37 U/L), alanine aminotransferase (ALT) 400 U/L (normal 30–65 U/L), total bilirubin 1.97 mg/dL (normal 0.10–1.10 mg/dL), direct bilirubin 0.94 mg/dL (normal 0–0.30 mg/dL), alkaline phosphatase 165 U/L (normal range 40–134 U/L), and gamma glutamyltransferase (GGT) 212 U/L (5–85 U/L).

With the patient under general anesthesia, a percutaneous 10-Fr abdominal drainage was placed using ultrasound guidance, and was connected to an external biliary catheter. At the same time, endoscopic retrograde cholangiopancreatography (ERCP) was done to rule out possible biliary leakage. The choledochus was cannulated and a large bile leak was observed (● Fig. 1). Because of the size of the leak, a self expandable metallic stent (10 cm × 1 cm, Wallstent; Boston Scientific, Massachusetts, USA) was placed across the leak (● Fig. 2). Finally, a 10-Fr Ring external-internal biliary catheter (Boston Scientific) was also inserted so that the bile output could be monitored.

The patient was discharged 5 days later, in good general condition, asymptomatic and without fever. The internal-external biliary catheter and the biliary stent were removed 2 months later, and there was complete resolution of the fistula (● Fig. 3 and 4). After 6 months, the patient remained in a good general condition, with no evidence of recurrence of the biliary leak.



**Fig. 4** Normal cholangiographic findings after stent removal.

#### Bibliography

**DOI** 10.1055/s-2008-1077695

Endoscopy 2009; 41: E4–E5

© Georg Thieme Verlag KG Stuttgart · New York ·  
ISSN 0013-726X

#### Corresponding author

**M. Di Pisa, MD**

Department of Gastroenterology

IsMeTT, UPMC

Via Tricomi 1

Palermo

Italy 90100

Fax: +39-91-2192400

mdipisa@ismett.edu

Endoscopy\_UCTN\_Code\_TTT\_1AR\_2AG

**M. Di Pisa, M. Traina, R. Miraglia,  
R. Volpes, S. Gruttadauria, A. Luca,  
B. Gridelli**

IsMeTT, UPMC, Palermo, Italy

#### References

- 1 *Stratta RJ, Wood Rp, Langnas AN et al.* Diagnosis and treatment of biliary tract complications after orthotopic liver transplantation. *Surgery* 1989; 106: 675–683
- 2 *Thulavath PJ, Atassi T, Lee J.* An endoscopic approach to biliary complications following orthotopic liver transplantation. *Liver Int* 2003; 23: 156–162
- 3 *Bourgeois N, Deviere J, Yeaton P et al.* Diagnostic and therapeutic endoscopic retrograde cholangiography after liver transplantation. *Gastrointest Endosc* 1995; 42: 527
- 4 *Baron TH, Poterucha JJ.* Insertion and removal of covered expandable metal stents for closure of complex biliary leaks. *Clin Gastroenterol Hepatol* 2006; 4: 381–386
- 5 *Kahaleh M, Sundaram V, Condron SL et al.* Temporary placement of a covered self-expandable metallic stents in patients with biliary leak: midterm evaluation of a pilot study. *Gastrointest Endosc* 2007; 66: 52–59. Epub Feb 26 2007