

Endoscopic placement of a covered self-expandable metal stent in the minor papilla in patients with chronic pancreatitis and pancreas divisum

Pancreas divisum is the most common anatomic variant of pancreatic development and may lead to chronic pancreatitis [1,2]. Endoscopic stenting of the dorsal pancreatic duct is a safe and effective treatment for patients with chronic pancreatitis and pancreas divisum [3,4]. Here we report three cases of chronic pancreatitis and pancreas divisum successfully treated with endoscopic placement of a self-expanding metal stent (SEMS) in the minor papilla.

Between June 2005 and July 2006, three patients with chronic pancreatitis and pancreas divisum received a SEMS for relief of abdominal pain that was persisting despite several attempts at pancreatic plastic stent implantation (Wilson-Cook Medical GI Endoscopy, Winston-Salem, NC, USA). All patients received a covered pancreatic-type SEMS (Taewoong Medical Co., Seoul, South Korea), which was implanted into the minor papilla and the dorsal pancreatic duct using a standard technique with a duodenoscope (TJF-140 or TJF-160, Olympus Corp., Japan). All three endoscopic SEMS placements were successful and there were no complications relating to endoscopic retrograde cholangiopancreatography (ERCP). Interestingly, 6 months after implantation, both a plain abdominal radiograph and duodenoscopy showed that all three SEMS had passed spontaneously (● Fig. 1).

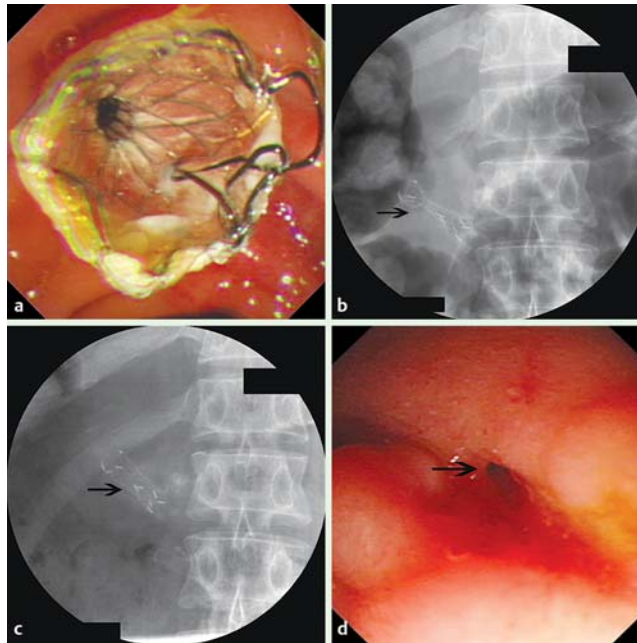


Fig. 1 Endoscopic placement of a covered self-expandable metal stent (SEMS) in a patient with chronic pancreatitis and pancreas divisum. **a** Endoscopic view of the SEMS in the minor papilla. **b** A waist is visible in the stent. **c** The stricture in the minor papilla has been dilated successfully with disappearance of the stent waist 2 weeks after SEMS implantation. **d** Endoscopic view of the minor papilla 6 months after SEMS implantation. The orifice of the minor papilla has enlarged significantly.

ERCP showed no new stones in the dorsal pancreatic duct and no further intervention was carried out. At a mean follow-up of 27 months (rang 25–30 months), all patients were free of pain and none had steatorrhea or diabetes mellitus (● Table 1).

The results of our pilot trial with three patients suggests that covered SEMS should be considered as an alternative to the en-

doscopic management of chronic pancreatitis and pancreas divisum. Moreover, as all SEMS passed spontaneously through the minor papilla and dorsal pancreatic duct, further endoscopic extraction was not required.

Endoscopy_UCTN_Code_TTT_1AR_2AZ
Endoscopy_UCTN_Code_TTT_1AR_2AI

Table 1 Patient and stent data and pain scores.

Patient	Age/sex	No. of sessions of PS placement	SEMS (diameter, length)	Pain score (VAS)			Follow-up (month)
				Pre-PS	Post-PS	After SEMS	
1	58/M	3 (7 F, 8.5 F, 10 F)	8 mm, 30 mm	8	7	0	30
2	47/M	2 (7 F, 8.5 F)	8 mm, 30 mm	7	6	0	26
3	43/M	3 (7 F, 8.5 F, 10 F)	8 mm, 30 mm	6	4	0	25

PS, plastic stent; F, French; SEMS, self-expandable metal stent; VAS, visual analog scale (0 = no pain; 10 = [imaginary] maximum pain).

Z. Liao, Z. S. Li, W. Wang, Z. Ye, X. W. Lai, X. T. Wang, D. W. Zou
Chronic Pancreatitis Study Group,
Department of Gastroenterology,
Digestive Endoscopy Center, Changhai
Hospital, Second Military Medical
University, China

References

- 1 Klein SD, Affronti JP. Pancreas divisum, an evidence-based review: part I, pathophysiology. *Gastrointest Endosc* 2004; 60: 419–425
- 2 Klein SD, Affronti JP. Pancreas divisum, an evidence-based review: part II, patient selection and treatment. *Gastrointest Endosc* 2004; 60: 585–589
- 3 Vitale GC, Vitale M, Vitale DS et al. Long-term follow-up of endoscopic stenting in patients with chronic pancreatitis secondary to pancreas divisum. *Surg Endosc* 2007; 21: 2199–2202
- 4 Liao Z, Gao R, Wang W et al. A systematic review on endoscopic detection rate, endotherapy, and surgery for pancreas divisum. *Endoscopy* 2009; 41: 439–444

Bibliography

DOI 10.1055/s-0029-1214851
Endoscopy 2009; 41: E302–E303
© Georg Thieme Verlag KG Stuttgart · New York ·
ISSN 0013-726X

Corresponding author

Professor Z. S. Li

Department of Gastroenterology
Digestive Endoscopy Center
Changhai Hospital
Second Military Medical University
168 Changhai Road
Shanghai 200433
China
Fax: +86-21-55621735
zhaoshenli@hotmail.com