

Esophageal nitinol stent dysfunction because of fracture and collapse

A 40-year-old man, a long-term smoker, presented with progressively increasing dysphagia associated with loss of appetite and weight. The general physical and systemic examination was normal. Routine investigations, including hemogram, blood biochemistry and a chest radiograph were also normal.

Upper gastrointestinal endoscopy revealed a polypoidal growth in the mid-esophagus. The endoscope could not be negotiated beyond the growth. Histopathological examination of the endoscopic biopsies was suggestive of squamous cell carcinoma. The patient was treated with radiotherapy. However, the dysphagia persisted and patient was referred to us for insertion of a self-expanding metallic stent (SEMS). After obtaining informed consent, a nitinol SEMS (11 cm Choo stent (M. I. Technical, Seoul, South Korea) was placed across the stricture, which resulted in marked relief of dysphagia.

Fifteen months later, the patient reported back with progressively increasing dysphagia. An upper gastrointestinal endoscopy revealed that the SEMS had collapsed at places, and the wire mesh was broken with ingrowth of tumor (● Fig. 1). Under fluoroscopic and endoscopic guidance, a 14 cm nitinol SEMS (Choo stent, M. I. Technical, Seoul, South Korea) was placed within the previously placed stent (● Fig. 2).

There was marked relief of dysphagia and the patient remained asymptomatic after 5 months of follow-up.

SEMS are commonly used for palliation in patients with malignant dysphagia and typical complications may be acute (including hemorrhage, ulceration, perforation or fistula, compression of the trachea, malposition, delivery system entrapment, stent dislodgment) or chronic (gastroesophageal reflux disease/recurrent

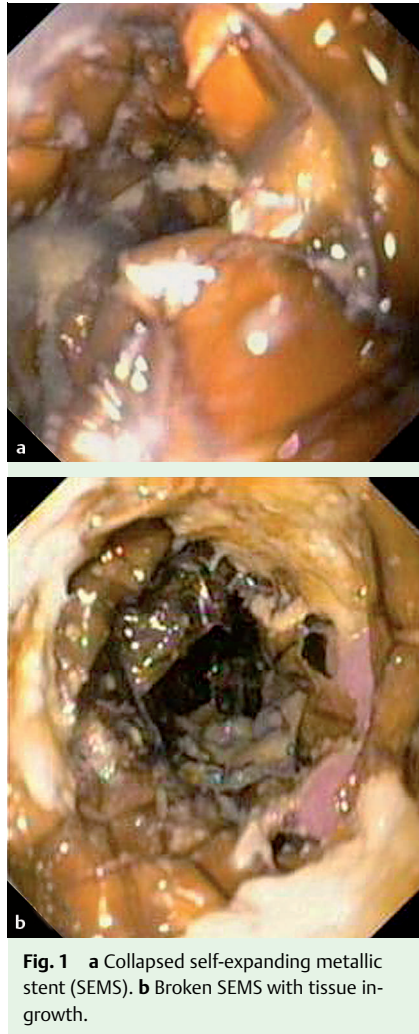


Fig. 1 a Collapsed self-expanding metallic stent (SEMS). b Broken SEMS with tissue ingrowth.

aspirations, re-obstruction, stent migration, tracheoesophageal fistula, late bleeding and tumor ingrowth) [1]. Collapse and fracture of an esophageal stent is a rare complication, and manifests as vomiting, dysphagia, or small bowel obstruction [2–5]. Esophageal stents, once in place and expanded, are not subject to any great mechanical stress, and corrosion is the most likely

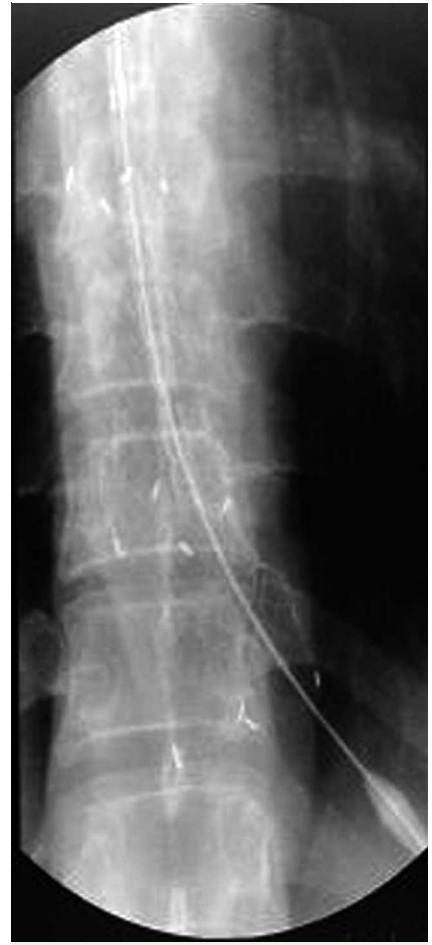

Fig. 2 Deployment of a new self-expanding metallic stent (SEMS) over the collapsed SEMS.

cause of late fractures of the esophageal stent. Other causes could be thermal overstrain induced by laser application, or defective material at the time of deployment or spontaneous fracture [2–5]. As the present patient survived for a long period after insertion of the first stent, the corrosion caused by prolonged presence of the SEMS in the esophagus could have caused it to collapse.

Endoscopy_UCTN_Code_CPL_1AH_2AD

**S. S. Rana, D. K. Bhasin, G. S. Sidhu,
P. Rawal, B. Nagi, K. Singh**

Department of Gastroenterology, Post
Graduate Institute of Medical Education
and Research, Chandigarh, India

References

- 1 *Baron TH*. Minimizing endoscopic complications: endoluminal stents. *Gastrointest Endoscopy Clin North Am* 2007; 17: 83–104
- 2 *Schoefl R, Winkelbauer F, Haefner M et al*. Two cases of fractured esophageal Nitinol stents. *Endoscopy* 1996; 28: 518–520
- 3 *Grimley CE, Bowling TE*. Oesophageal metallic stent dysfunction: first reported case of stent fracture and separation. *Endoscopy* 1999; 31: 45
- 4 *Reddy AV, Alwair H, Trewby PN*. Fractured esophageal Nitinol stent: report of two fractures in the same patient. *Gastrointest Endosc* 2003; 57: 138–139
- 5 *Chhetri SK, Selinger CP, Greer S*. Fracture of an esophageal stent. *Endoscopy* 2008; 40: E199

Bibliography

DOI 10.1055/s-0029-1214771

Endoscopy 2009; 41: E170–E171

© Georg Thieme Verlag KG Stuttgart · New York ·
ISSN 0013-726X

Corresponding author

Dr. S. S. Rana, MD, DM

Department of Gastroenterology
Postgraduate Institute of Medical Education and
Research (PGIMER)

Chandigarh – 160012

India

Fax: +91-172-2744401

drsurrinderrana@yahoo.co.in;

sonalisurinder@yahoo.co.in